

Clinical characteristics in focal cortical dysplasia: a retrospective evaluation in a series of 120 patients

Susanne Fauser,¹ Hans-Juergen Huppertz,¹ Thomas Bast,⁴ Karl Strobl,⁵ Georgios Pantazis,² Dirk-Matthias Altenmueller,¹ Bertram Feil,¹ Sabine Rona,¹ Christoph Kurth,⁵ Dietz Rating,⁴ Rudolf Korinthenberg,³ Bernhard J. Steinhoff,⁵ Benedikt Volk² and Andreas Schulze-Bonhage¹

¹Epilepsy Centre, ²Department of Neuropathology, ³Department of Neuropediatrics and Muscular Diseases, University of Freiburg, ⁴Department of Pediatric Neurology, University of Heidelberg and ⁵Epilepsy Centre Kork, Kehl-Kork, Germany

Correspondence to: Susanne Fauser, Epilepsy Center, University of Freiburg, Breisacher Street 64, 79106 Freiburg, Germany
E-mail: fauser@nz11.ukl.uni-freiburg.de

Focal cortical dysplasias (FCDs) are increasingly diagnosed as a cause of symptomatic focal epilepsy in paediatric and adult patients. However, little is known about the clinical characteristics of epilepsy in these patients. In order to elucidate the clinical characteristics of their epilepsy, 120 pharmacoresistant patients including children and adults with histologically proven FCD were studied retrospectively. Age at seizure onset was analysed in the total group and compared between subgroups with different localization and different histological subtypes of FCD. The role of febrile seizures with respect to dual pathology was investigated. Seizure semiology was analysed focusing on initial seizure type and change of seizure semiology during the course of disease. Finally, transient responsiveness to antiepileptic drug therapy was studied. In the majority of patients, epilepsy began in the first 5 years of life. However, onset of epilepsy could also occur in the second or third decade until the age of 60. Age at epilepsy onset was not significantly different between temporal, extratemporal and multilobar localization of FCD. Patients without cytoarchitectural abnormalities (mild malformations of cortical development, FCD 1a according to Palmini) had significantly later epilepsy onset ($P = 0.001$) compared with patients with cytoarchitectural abnormalities (FCD 1b, 2a and 2b according to Palmini). In patients with additional hippocampal sclerosis (dual pathology) febrile seizures were significantly more frequently reported ($P = 0.02$) than in patients without dual pathology. Moreover, patients with dual pathology and febrile seizures significantly more frequently presented with severe hippocampal sclerosis (Wyler Grade 3–4) as compared with patients with dual pathology in the absence of febrile seizures ($P = 0.03$). First observed seizures were mainly tonic or generalized tonic-clonic. A change of seizure semiology seemed to be age-dependent and occurred between the age of >1 and 14 years. About 15.8% of the patients presented with status epilepticus during the course of disease. About 17% of the patients showed transient responsiveness (≥ 1 year seizure freedom) to antiepileptic drug therapy either after initial therapy (50%) or later in the course of epilepsy (50%). Patients with FCD represent a heterogeneous group. Different age at epilepsy onset and transient responsiveness to antiepileptic drugs in ~17% of patients may reflect different dynamics in epileptogenicity of the underlying FCD. Dual pathology may be associated with different pathomechanisms in patients with and without febrile seizures.

Keywords: focal cortical dysplasia; clinical characteristics; semiology; status epilepticus

Abbreviations: FCD = focal cortical dysplasia; mMCD = mild malformations of cortical development; MTD = mesial temporal damage

Received December 29, 2005. Revised March 17, 2006. Accepted April 20, 2006. Advance Access publication May 19, 2006

Introduction

Malformations of cortical development are a frequent cause of symptomatic focal epilepsy in childhood and adulthood. In particular, focal cortical dysplasia (FCD) is increasingly recognized in epilepsy patients owing to improved MRI techniques including post-processing of 3D data sets (Palmini *et al.*, 1991*b*; Kuzniecky *et al.*, 1995; Chan *et al.*, 1998; Bastos *et al.*, 1999; Kassubek *et al.*, 2002; Wilke *et al.*, 2003; Huppertz *et al.*, 2005). Nowadays, FCD is identified in 20–25% of patients with focal epilepsy (Kuzniecky *et al.*, 1993; Tassi *et al.*, 2002). About 76% of the patients are supposed to suffer from pharmacoresistant epilepsy (Semah *et al.*, 1998). Surgical treatment offers a promising therapy option in these patients (Kral *et al.*, 2003; Fauser *et al.*, 2004).

Although FCD obviously represents a frequent cause of epilepsy, early features such as age at epilepsy onset, semiology of initial seizures and the role of febrile seizures in dual pathology (FCD associated with hippocampal sclerosis) are poorly known. Only few studies have so far focused their interest on clinical features in patients with FCD (Chassoux *et al.*, 2000; Lortie *et al.*, 2002; Bautista *et al.*, 2003; Widdess-Walsh *et al.*, 2005). Moreover, studies involving only children may be biased with respect to age at epilepsy onset and semiology.

There is only sparse knowledge of the course of the disease. Few reports have dealt with questions such as transient responder rates to antiepileptic drugs or time to intractability (Palmini *et al.*, 1991*a*; Semah *et al.*, 1998; Stephen *et al.*, 2001; Widdess-Walsh *et al.*, 2005), change of seizure semiology during the course of disease or the incidence of generalized convulsive or focal status epilepticus (Palmini *et al.*, 1991*a*; Chassoux *et al.*, 2000). Furthermore, in several studies (e.g. Semah *et al.*, 1998 and Stephens *et al.*, 2001) malformations classified as cortical dysplasia were heterogeneous and not histologically confirmed, including not only FCD but also other malformations of cortical development (e.g. grey matter heterotopia and tuberous sclerosis).

To elucidate the initial clinical characteristics and the clinical course of epilepsy in patients with FCD, in this study a series of 120 operated patients with histologically confirmed FCD including children and adults was retrospectively investigated.

Patients and methods

Patients

The medical charts of 120 patients with FCD were retrospectively analysed. Pre-surgical evaluation was performed in the Epilepsy Centres of Freiburg, Heidelberg and Kork, Germany. All patients were referred to the Epilepsy Centre of the University of Freiburg, Germany, for epilepsy surgery because of pharmacoresistant epilepsy between 1998 and 2005. During this time span, a total of 1465 patients underwent invasive or non-invasive pre-surgical epilepsy monitoring. Five hundred and twenty-two of these patients underwent resective epilepsy surgery. Histological diagnosis of FCD was available in all 120 patients.

Among the 120 FCD patients were 54 children (<16 years) and 66 adults (≥ 16 years). The age at epilepsy surgery ranged from 1 to 66 years. Data extracted from the charts included age at the time of first seizure, semiology of first seizure, seizure semiology during the course of disease, the presence or absence of febrile seizures, the presence or absence of dual pathology, the site of FCD based on MRI, the response to pharmacotherapy and the histological diagnosis.

Putative aetiologies (based on MRI) and syndromic diagnosis (based on semiology) prior to surgery

The putative aetiologies of epilepsy based on MRI findings prior to epilepsy surgery in these patients were as follows: an FCD in 57 patients, an FCD associated with hippocampal sclerosis in 21 patients, a hippocampal sclerosis combined with temporal lobe atrophy in 2 patients, a hippocampal sclerosis in 5 patients, a grey matter heterotopia in 2 patients, a low-grade tumour (ganglioglioma, DNET) in 8 patients, an ulegyria/hypoxia in 2 patients and a gliosis in 5 patients (supposed to be the sequel of a contusion, bleeding or encephalitis) and cryptogenic in 18 patients.

Pre-surgical syndromes diagnosed according to the semiology were as follows: temporal lobe epilepsy in 57 patients, frontal lobe epilepsy in 33 patients, occipital lobe epilepsy in 6 patients and parietal lobe epilepsy in 4 patients. In 8 patients with seizure onset between <1 and 2 years of age, the initial diagnosis was a West syndrome. In the later course, four of these patients presented with a frontal, two with an occipital and two with a temporal semiology. In 12 patients semiology was not indicative for a particular lobe. In none of the patients a Lennox–Gastaut syndrome was diagnosed.

Histology

Histological dysplastic features were classified as suggested by Palmini (Palmini and Lüders, 2002): dyslamination was the inclusion criterion for the diagnosis of FCD.

FCD 1a was defined as a blurred transition between different cortical layers, in our patient group most commonly seen between layers III and IV or layers V and VI. In these zones we observed a relatively homogeneous population of neurons and a moderately increased cell density. Occasionally, dyslamination was characterized by a numerical reduction of pyramidal neurons and granule cells and clusters of misplaced neurons (e.g. an increased number of pyramidal neurons in layers I or II with abundant ectopic neurons in the white matter).

FCD 1b was diagnosed if the laminar disorganization was more prominent and occurred together with cytoarchitectural abnormalities such as immature neurons (a population of neurons with a large nucleus and a thin rim of cytoplasm) and/or giant neurons.

Dysplastic tissue with the additional occurrence of dysmorphic neurons was classified as FCD 2a, and dysplastic tissue with additional balloon cells as FCD 2b.

Abundant heterotopic white matter neurons in the absence of dyslamination were described as mild malformations of cortical development (mMCD).

The histological grading of hippocampal pathology was classified according to Wyler (Wyler *et al.*, 1995): Grade 1: mild mesial temporal damage (MTD) with gliosis and <10% or no hippocampal neuronal dropout involving sectors CA1, CA3 and/or CA4 of hippocampal pyramidal cell layer. Grade 2: moderate MTD

with gliosis and 10–50% neuronal dropout involving sectors CA1, CA3 and/or CA4 of hippocampal pyramidal cell layer. Grade 3: moderate to marked MTD with gliosis and >50% neuronal dropout involving sectors CA1, CA3 CA4 of hippocampal pyramidal cell layer but sparing CA2. Grade 4: marked MTD with gliosis and >50% neuronal dropout involving all sectors of hippocampal pyramidal cell layer.

Only patients with histologically proven FCD were included in this series as MR imaging may have a considerable amount of both false negative and false positive findings in patients with FCD.

Seizure semiology

The seizure classification suggested by the ILAE (Engel, 1998) did not allow a proper classification in our patient group as the majority of patients had their first seizures in early infancy, and therefore in 39% of the patients the state of consciousness could not be assessed.

Therefore, seizure types were classified according to the semiological seizure classification suggested by Lüders *et al.* (1998, 1999). Seizure types occurring in our patient group were auras (including auras with sensory, psychosensory and experiential symptoms), motor seizures (simple motor: myoclonic, tonic, clonic, tonic-clonic and versive; complex motor: with hypermotor or automotor movements) and special seizures characterized by ‘negative’ features (atonic, astatic, hypomotor). Epileptic spasms were separately mentioned.

A change in seizure semiology was defined as the occurrence of a new seizure type according to the classification of Lüders *et al.* (1998, 1999), for example, a change from hypomotor to tonic seizures. Variations in the evolution of seizure types (e.g. secondary generalization or not) were not considered as a change of seizure semiology.

Statistics

The chi-square test was used for comparison of categorical data (i) to compare the occurrence of dual pathology in patients with and without febrile seizures; and (ii) to compare the occurrence of severe hippocampal sclerosis (Wyler 3–4) in patients with and without febrile seizures. The Kruskal–Wallis test and the Mann–Whitney test were used as non-parametric tests for the comparison of age at epilepsy onset in different subgroups (i) in relation to the localization; (ii) in relation to histology, that is, comparing patients with and without cytoarchitectural abnormalities; and (iii) in relation to the presence or absence of dual pathology. *P*-values < 0.05 were regarded as statistically significant.

Results

Age at epilepsy onset

Age at epilepsy onset in the total series

The age at epilepsy onset in the total series of FCD patients is shown in Fig. 1. The age at epilepsy onset ranged from <1 to 60 years (mean: 5.8 years, median: 3 years). In 61% of the patients epilepsy started before the age of 5 years, and in 92.5% of the patients before the age of 16 years.

Age at epilepsy onset in relation to localization

The age at epilepsy onset in relation to localization is shown in Fig. 2. In patients with FCD localization in the temporal lobe ($n = 55$), age at epilepsy onset ranged from <1 to 60 years

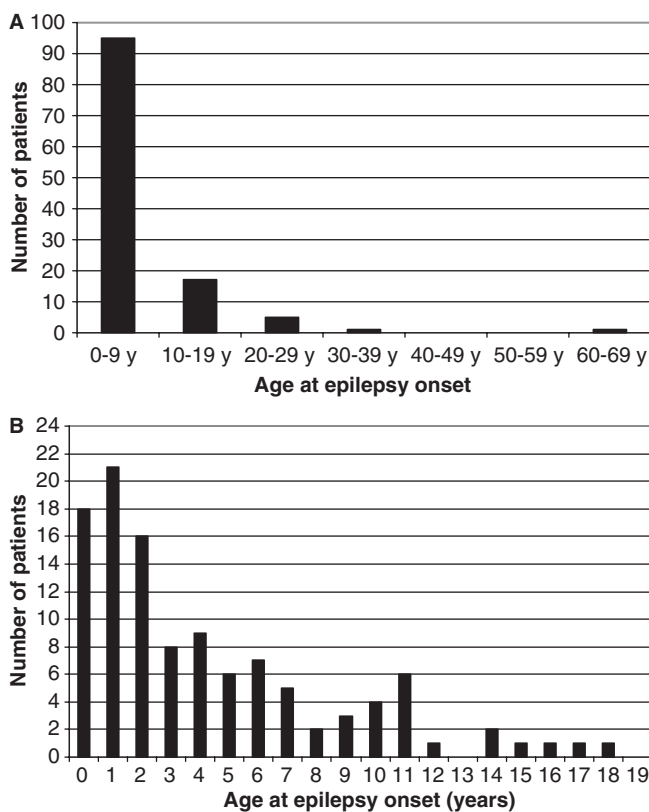


Fig. 1 Age at epilepsy onset in the total series of FCD patients. **(A)** Overview over 7 decades. **(B)** Age at epilepsy onset in a subset of patients in whom seizures started before 20 years of age.

(mean: 7.2 years, median: 4 years). In patients with unilobar extratemporal localized FCD ($n = 39$: 35 frontal, 2 parietal and 2 occipital), age at epilepsy onset ranged from <1 to 31 years (mean: 4.7 years, median: 3 years). In patients with multilobar FCD ($n = 25$), age at epilepsy onset ranged from <1 to 22 years (mean: 4.0 years, median: 2 years). In one patient, age at epilepsy onset was unknown. The distribution pattern of age at epilepsy onset was similar in all groups.

Age at epilepsy onset in relation to histology

The age at epilepsy onset in relation to histology is shown in Fig. 3. An early epilepsy onset (age <5 years) in the majority of patients is observed in patients with FCD 1a ($n = 25$, range: <1–60 years, mean: 8.6 years, median: 4 years) and even more evident in patients with FCD 1b ($n = 36$, range: <1–29 years, mean: 4.4 years, median: 2.5 years), FCD 2a ($n = 24$ years, range: <1–26 years, mean: 4.1 years, median: 1.5 years) and FCD 2b ($n = 23$, range: <1–31 years, mean: 4.5 years, median: 2 years).

In patients with mMCD, however, age at epilepsy onset seemed to be homogeneously distributed over the first two decades ($n = 11$, range: 1–20 years, mean: 9.9 years, median: 10 years). In one patient age at epilepsy onset was unknown.

On comparing histological subgroups without cytoarchitectural abnormalities (Tassi *et al.*, 2002) corresponding to

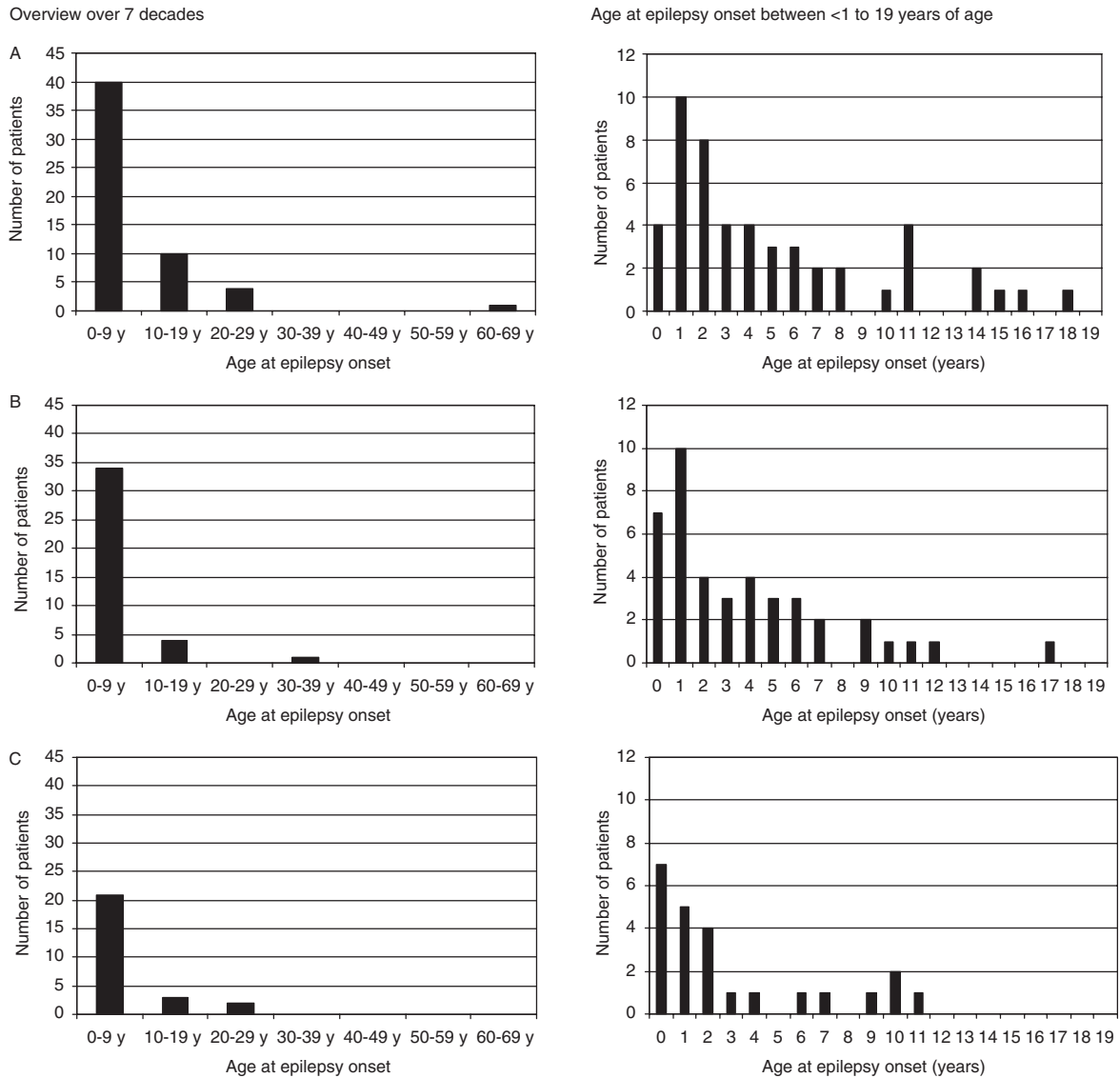


Fig. 2 Age at epilepsy onset in relation to localization. **(A)** Temporal FCD. **(B)** Extratemporal FCD. Overview over 7 decades. Age at epilepsy onset between <1 and 19 years of age. **(C)** Multilobar FCD. Overview over 7 decades. Age at epilepsy onset between <1 and 19 years of age.

mMCD and FCD 1a versus histological subtypes with cytoarchitectural abnormalities corresponding to FCD 1b, 2a and 2b, it was found that the differences in age at epilepsy onset were statistically significant ($P = 0.001$).

Age at epilepsy onset in relation to presence or absence of dual pathology

In patients with dual pathology (FCD located in the temporal lobe or temporo-occipitally and an additional hippocampal sclerosis) ($n = 48$), age at epilepsy onset ranged from <1 to 29 years (mean: 6.2 years, median: 3 years). In patients without dual pathology (FCD located in the temporal lobe or temporo-occipitally) ($n = 23$), age at epilepsy onset ranged from <1 to 60 years (mean: 7.0 years, median: 3 years). In patients with dual pathology age at epilepsy onset in patients with mild (Wyler 1–2) and severe (Wyler 3–4) hip-

pocampal sclerosis was similar (Wyler 1–2: range: <1–29 years, mean: 7.9 years, median: 3 years; Wyler 3–4: range: <1–20 years, mean: 4.4 years, median: 3 years). The distribution pattern of age at epilepsy onset was similar in both groups.

Association with febrile seizures

In 92 patients, information on the presence or absence of febrile seizures was available. In patients with febrile seizures ($n = 16$), 13 had temporal or multilobar FCD including the temporal lobe, and 3 patients had extratemporal FCD. Among the patients with FCD including the temporal lobe, 12 (92%) had dual pathology. Nine of them (75%) showed severe hippocampal sclerosis (Wyler 3–4) and three (25%) showed mild hippocampal sclerosis (Wyler 1–2). None of the patients with extratemporal FCD had dual pathology (Table 1).

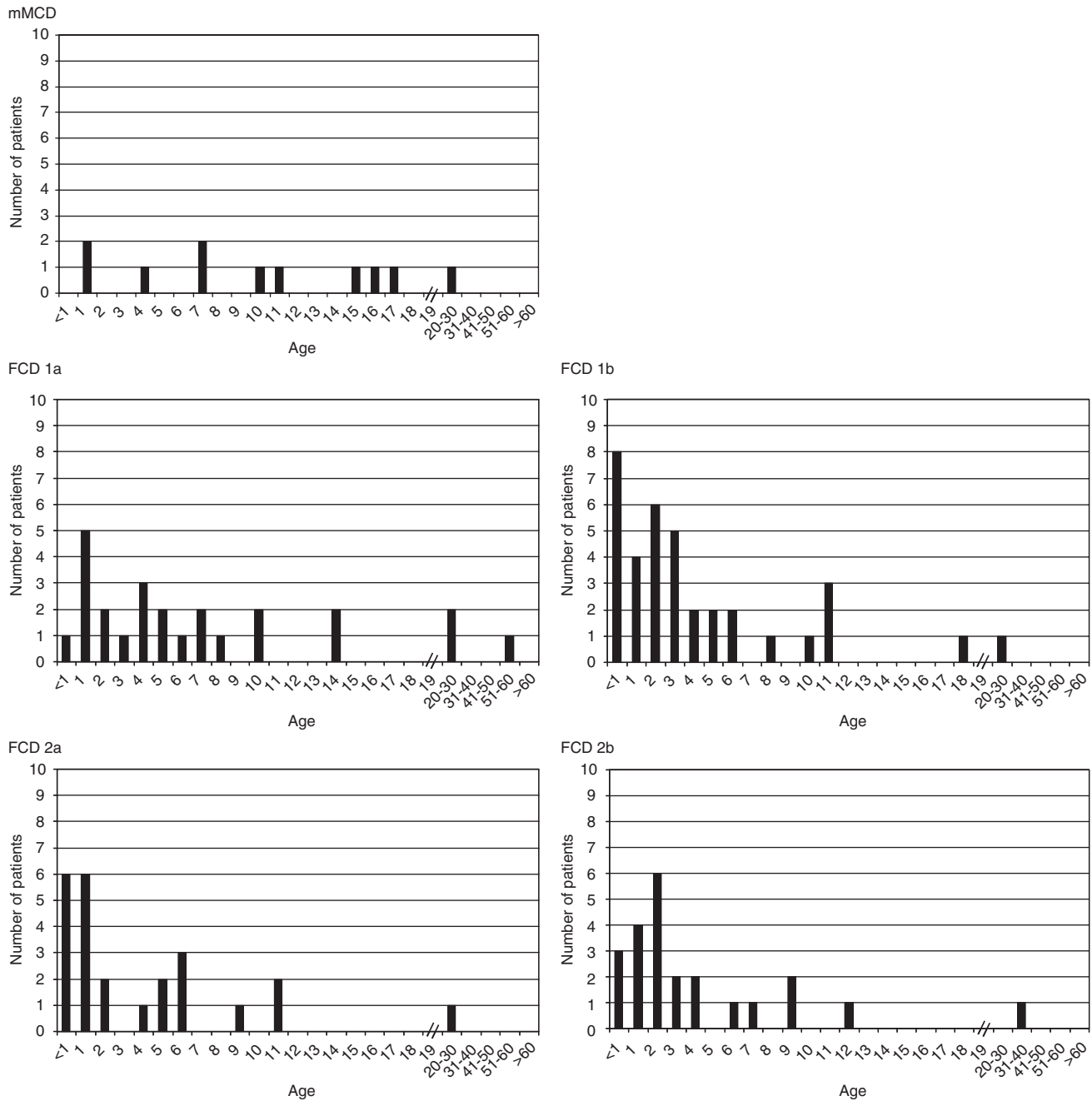


Fig. 3 Age at epilepsy onset in relation to histology.

In patients without febrile seizures ($n = 76$), 43 had FCD in the temporal or multilobar FCD including the temporal lobe, and 33 patients had extratemporal FCD. Among the patients with FCD including the temporal lobe, 24 (56%) had dual pathology. Nine of them (38%) had severe hippocampal sclerosis (Wyler 3–4) and 15 (62%) had mild hippocampal sclerosis (Wyler 1–2). None of the patients with extratemporal FCD had dual pathology (Table 2).

Statistical analysis revealed that dual pathology was significantly more frequent ($P = 0.02$) in patients with febrile seizures compared with patients without febrile seizures, and

that the proportion of patients with severe hippocampal sclerosis (Wyler 3–4) was significantly higher ($P = 0.03$) in patients with febrile seizures compared with patients without febrile seizures.

Semiology

Semiology of the first seizure

A description of the first seizure was available in 107 patients. Generalized tonic–clonic seizures were described in 22 patients (20.6%), tonic seizures in 17 patients (15.9%), hypomotor seizures in 15 patients (14.0%), auras with

Table 1 Overview of patients with febrile seizures

Total 16			
Temporal 13 (81%)		Extratemporal 3 (19%)	
Dual pathology 12 (92%)	No dual pathology 1 (8%)	Dual pathology 0 (0%)	No dual pathology 3 (100%)
Wyller 1–2 3 (25%)	Wyller 3–4 9 (75%)		

Table 2 Overview of patients without febrile seizures

Total 76			
Temporal 43 (57%)		Extratemporal 33 (43%)	
Dual pathology 24 (50%)	No dual pathology 19 (50%)	Dual pathology 0 (0%)	No dual pathology 33 (100%)
Wyller 1–2 15 (62%)	Wyller 3–4 9 (38%)		

subsequent simple motor or complex motor seizures in 10 patients (9.3%), epileptic spasms in 8 patients (7.5%), atonic seizures in 7 patients (6.5%), automotor seizures in 5 patients (4.7%), isolated auras in 4 patients (3.7%), focal clonic seizures in 4 patients (3.7%), versive seizures in 3 patients (2.8%) and hypermotor seizures in 1 patient (0.9%), and unclassifiable descriptions were available in 10 patients (9.3%). A relation of seizure semiology to the respective age of the patient is shown in Table 3.

A loss of consciousness was reported in 54 patients (50%) (classified as secondary generalized tonic–clonic seizures in 22 patients and as complex partial seizures in 32 patients according to the ILAE). Preserved consciousness was reported in 10 patients (9%) (classified as simple partial seizures according to the ILAE). In 42 patients (39%) no information about the state of consciousness was available.

Initial manifestation of epilepsy through a generalized tonic–clonic seizure was observed in 15 out of 65 (23%) patients with temporal or temporo-occipital FCD, 4 out of 35 (11%) patients with frontal FCD and 3 out of 10 (30%) patients with parieto- and/or occipital FCD.

Initial manifestation of epilepsy through epileptic spasms was seen in three patients with frontal FCD, one patient with temporal FCD, two patients with temporo-occipital FCD and two patients with parieto-occipital FCD.

Change in seizure semiology during the course of disease

A change in seizure semiology over time was reported in 63 patients; unchanged seizure semiology was reported in 38 patients. In 19 patients, no information on the development of seizure semiology was available. The occurrence of a change in seizure semiology was age-dependent. All patients

Table 3 Initial seizure type in relation to the age of the patient

Spasms	●●●●●●	●●				
Hypomotor	●	●●●●●●●●	●	●●	●	●●
Tonic	●●	●●●●●●●●	●●●	●●●●		●
Gtcs	●●●●	●●●●●●	●●●	●●●●	●●●	●●
Atonic	●	●●●●	●●			
Focal clonic	●		●●	●		
Isolated aura		●	●●		●	
Aura > motor		●●	●●●●	●●●	●	
Automotor		●●		●		●●
Versive			●	●		●
Hypermotor					●	
Unclassifiable	●●	●●	●●	●●	●●	
No description	●	●●●	●●	●●●●	●	●●
Age at onset	<1 year	1–2 years	2–5 years	6–10 years	11–15 years	>15 years

in whom a change in seizure semiology was documented had seizure onset before the age of 12 years (mean: 3.5 years, median: 2 years). New seizure types appeared exclusively between <1 and 14 years of age. In patients with unchanged seizure semiology, the age at epilepsy onset was much more variable, ranging from <1 to 60 years (mean: 10.2 years, median: 5.5 years). In both groups, the duration of epilepsy was comparable (patients with change in semiology: mean: 12 years, median: 10 years; patients without change in semiology: mean: 14 years, median: 10 years). Thirty patients (48%) with changes in semiology and 10 patients (26%) without changes in semiology were operated before the age of 14 years. Thus, the differences between patients with and without change in seizure semiology cannot be explained by differences in the duration of epilepsy, the age at epilepsy surgery or longer observation periods.

Status epilepticus and series of generalized convulsive seizures

In our patient group, 19 patients (15.8%) were reported to have status epilepticus. Seven patients had a generalized tonic–clonic status epilepticus, 11 patients had a status epilepticus with partial motor (simple or complex motor) semiology and one patient had a confusional non-convulsive status epilepticus.

In addition, in three patients (2.5%) series of generalized tonic–clonic seizures were reported.

Response to pharmacotherapy

In our series of pharmacoresistant patients, in 20 patients (17%) a transient responsiveness to pharmacotherapy defined as a seizure-free period of at least 1 year was reported. There were few patients in whom the seizure-free period lasted 9–12 years. One patient with dual pathology remained seizure-free for 28 years (Fig. 4A).

In 14 patients, detailed information on the time of transient complete seizure control after epilepsy onset was

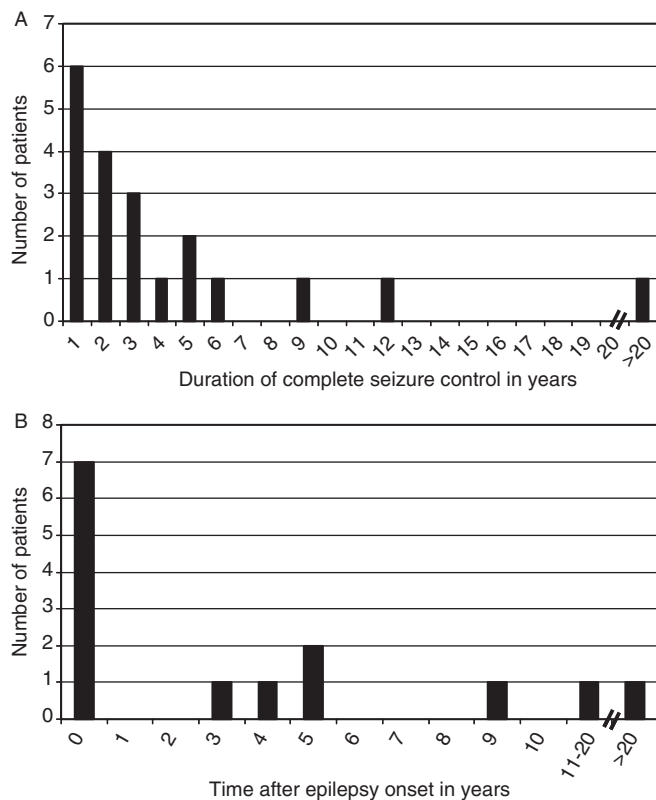


Fig. 4 (A) Duration of transient responsiveness to antiepileptic pharmacotherapy. (B) Time between epilepsy onset and achievement of transient seizure control.

available. In seven of these patients, transient complete seizure control could be achieved after initial therapy. However, in the remaining seven patients, transient complete seizure control was achieved 3–32 years after epilepsy onset (Fig. 4B).

The antiepileptic drugs or drug combinations that were taken during seizure-free periods were highly variable. Transient complete seizure control was achieved under monotherapy (carbamazepine: $n = 5$, valproate: $n = 1$, phenobarbital: $n = 1$, topiramate: $n = 1$, phenytoin: $n = 1$) or combination therapy (phenytoin and phenobarbital: $n = 2$, valproate and gabapentin: $n = 1$, carbamazepine and phenytoin: $n = 1$). Three patients remained seizure-free without medication (1–28 years). In four patients the medication during the seizure-free period was not known.

Discussion

In this study, clinical characteristics of epilepsy were analysed in 120 patients with histologically proven FCD, including both children and adults in order to identify possible clinical features of drug-resistant epilepsy associated with the underlying pathology.

Age at epilepsy onset

In the vast majority of patients, epilepsy onset occurred in the first 11 years of life. In a few patients epilepsy started

between the age of 12 and 31 years, and exceptionally later up to an age of 60 years. This latter patient did not become seizure-free after resection of the dysplastic area, which leaves the possibilities open that further subtle FCD contributed to epileptogenicity or that the epilepsy was caused by a completely different pathology, for example, by cerebrovascular disease. In both cases it could be assumed that cortical dysplasia can exist for prolonged periods of time without giving rise to clinically manifest seizures. It is tempting to speculate that there may be persons with cortical dysplasia but without the clinical manifestation of an epileptic syndrome.

Our data on the age at epilepsy onset are comparable with data reported by Palmieri *et al.* (1991a) in a group of 30 patients with FCD. In their group, age at epilepsy onset ranged from 0 to 21 years (mean: 5.7 years, median: 4.5 years). A further study by Siegel *et al.* (2005) analysed adult-onset epilepsy in patients with Taylor-type FCD. They found that in 10% of patients with Taylor-type FCD (corresponding to FCD 2a and b in our series) epilepsy onset was beyond the age of 18 years (range: 18–55 years). Although this number is much higher than in our series including children (adult onset in 6.5% of the total group and 4.2% in patients with FCD 2a and b corresponding to ‘Taylor-type FCD’), this study confirms the fact that even severe disturbances of the cortical lamination with abnormal cells can be silent over decades.

In our study, age at epilepsy onset in patients with temporal, extratemporal and multilobar FCD was similar. Accordingly, Lortie *et al.* (2002) could not find a correlation between age of onset and the topography of the lesion in a paediatric series of 28 patients with FCD.

The results of our study suggest that dysplastic tissue harbouring cytoarchitectural abnormalities (giant neurons, immature neurons, dysplastic neurons or balloon cells) (Tassi *et al.*, 2002) are associated with an earlier age at seizure onset than dysplastic tissue showing only architectural abnormalities. Especially the patient group with abundant heterotopic white matter neurons but no cortical dyslamination (i.e. patients with mMCD) seems to behave in a different way, as epilepsy onset seems to be homogeneously distributed over the first 2 decades of life. Similarly, a later epilepsy onset in patients with FCD type 1a compared with FCD 1b, 2a and 2b was observed by Widdess-Walsh *et al.* (2005). Although it could be shown that mild FCD also does have epileptogenic potential and may generate seizures (Fauser *et al.*, 2005), this supports the notion that dysmorphic neurons and giant neurons have a high epileptogenic potential (Cepeda *et al.*, 2003), and may thus contribute to an earlier manifestation of clinically manifest seizures.

Febrile seizures and dual pathology

In patients with an associated hippocampal sclerosis (dual pathology) the FCD was always located in the temporal lobe.

This observation may be explained in different ways, namely owing to a common underlying cause for both the cortical dysplasia in the temporal lobe and the hippocampal sclerosis (Raymond *et al.*, 1994) or owing to repeated seizure propagation into the hippocampus inducing structural changes in the hippocampal architecture (Holmes *et al.*, 1998; Huang *et al.*, 1999). The second theory may be supported by the fact that seizure propagation from the dysplastic temporal neocortex into the hippocampus is very rapid (1–26 s in one study, 17.3 s in another study) (Brekelmans *et al.*, 1995; Fauser *et al.*, 2005). Similar to mesial temporal sclerosis, febrile seizures were frequently observed in patients with dual pathology of the temporal lobe. In patients with febrile seizures, dual pathology was significantly more frequent than in patients without febrile seizures. Moreover, severe hippocampal sclerosis was significantly more frequently observed in the patients with dual pathology and a history of febrile seizures than in patients with dual pathology without a history of febrile seizures. Although this observation cannot clarify the question whether febrile seizures are the cause of hippocampal sclerosis or hippocampal sclerosis increases the susceptibility for febrile seizures (Fisher *et al.*, 1998; Hamati-Haddad and Abou-Khalil, 1998), it suggests that dual pathology may develop owing to different pathomechanisms. A congenital pathomechanism responsible for both pathologies may be present in the patient group with severe hippocampal sclerosis and febrile seizures. A secondary epileptogenesis due to repeated seizure propagation into the hippocampus may play a role in the patient group with mild hippocampal sclerosis and without febrile seizures. Further investigations on this topic are necessary.

Febrile seizures as a risk factor for FCD have been mentioned in recent studies (Bautista *et al.* 2003; Widdess-Walsh *et al.*, 2005). In the study performed by Bautista *et al.* (2003) febrile seizures were reported to be more frequent in patients with dual pathology as compared with those with isolated FCD, but without statistical significance. In the study by Widdess-Walsh *et al.* (2005) febrile seizures seemed to be more frequent in the history of patients with FCD 1a than in those with FCD 1b, 2a, or 2b. However, the presence or absence of a dual pathology was not mentioned in that study.

Seizure semiology

The semiology of the first observed seizures was described by the parents of the patient or by the patient himself. Having this in mind, generalized tonic-clonic seizures may be over-represented and milder focal seizures may have not been recognized as epileptic seizures and thus may be under-represented. Because of the high percentage of seizure onset in the first 2 years of life, statements on the state of consciousness were not possible in many patients.

Interestingly, hypermotor seizures were very rarely observed (0.8% of patients) as first seizure type even in frontal lobe FCD, but developed in 18% of patients over

time (between the ages of 4 and 13 years). This may result from the fact that epilepsy began in early childhood in the majority of patients. Age-related features in frontal lobe epilepsy in young children differing from those of adults have been reported by Fogarasi *et al.* (2001). In that study, hypermotor seizures or complex motor automatisms could not be recorded by video-monitoring in a group of 14 patients with frontal FCD at an age <7 years. Moreover, an age-dependency of seizure semiology is not specific for FCD and has been also observed in other patient groups with focal epilepsy of variable aetiology. In temporal lobe epilepsy, Brockhaus and Elger (1995) and Ray and Kotagal (2005) could show that seizures in young children have a different semiology compared with older children or adults. Children with epileptic spasms had FCD in different locations without clear preference of any lobe. Interestingly, all of them had left hemispheric lesions. A preponderance of left hemispheric lesions has already been observed by Cusmai (Cusmai *et al.*, 1988). A change in seizure semiology seems to be age-related (i.e. dependent on the maturation of the brain), and was reported until the age of 14 years. Our series did not contain any patient with adult onset of epilepsy in whom a change in seizure semiology was reported.

There have been a considerable number of case reports of patients with FCD who developed partial status epilepticus (Krsek *et al.*, 2002; Ng *et al.*, 2003; Yoshimura 2003; Misawa *et al.*, 2004; Misawa *et al.*, 2005), which might suggest that this is a frequent finding in this particular patient group. In our series, status epilepticus occurred in 15.8% of patients. This number is much lower as compared with a series reported by Palmiini (Palmiini *et al.*, 1991a) in which 30% of the patients had partial motor or generalized convulsive status epilepticus. The lower incidence in our series may be due to the location and extension of FCD. Partial motor status epilepticus was mainly reported in patients with central FCD, and generalized convulsive status epilepticus seemed to be associated with extensive structural abnormalities involving more than one lobe. In the series reported by Palmiini, 90% of the patients presented with multilobar FCD and 40% with central involvement as compared with only 22% of patients with multilobar FCD and only 6% with central involvement in our series. Thus, not the aetiology of FCD *per se* but the localization and extension of the lesion seem to be risk factors for status epilepticus.

Response to pharmacotherapy

In our study, no specific antiepileptic drug was revealed to be more effective than others in controlling seizures of FCD patients. Antiepileptic drugs under which the patients became transiently seizure-free seem to reflect their availability at the respective time.

The selection of patients with pharmacoresistant epilepsy in our series does not allow any general statement concerning the question whether epilepsy due to FCD can be controlled by antiepileptic drug treatment (Bast *et al.*, 2006). However,

our retrospective analysis showed that ~17% of pharmacoresistant patients did have transient seizure-free periods in their history. Seizure-freedom was not only achieved by initial antiepileptic therapy. In seven patients, seizure-freedom could be achieved later in the course of the disease.

The observation of a complete transient seizure control is in line with an investigation by Palmini who reported seizure-free periods of 2–11 years in a series of patients with FCD and pharmacoresistent epilepsy (Palmini *et al.*, 1991a).

Another study (Widdess-Walsh *et al.*, 2005) took the time to intractability, defined as more than two seizures per month despite at least two antiepileptic drugs, as a measure for epileptogenicity. The median time to intractability was 0 years in patients with each type of FCD; the range of the total group was between 0 and 38 years. In accordance with our observations this study shows that the majority of patients with FCD are pharmacoresistant from the beginning and that there are a few patients with low seizure frequency or good seizure control over several years. However, time to intractability as defined in that study is influenced by several factors, for example, not only by the epileptogenicity of the lesion but also by the strategies of the treating medical doctor. Moreover, this definition of intractability seems to be arbitrary as also patients with 1–2 seizures per month are considered as medically intractable, if more than two potent antiepileptic drugs have been applied in a sufficient dosage.

Nevertheless, in the vast majority of patients, no seizure-free period of >6 months could be achieved. This clearly shows that a tendency for insufficient seizure control can be established early in the course of disease in most patients with FCD. Early epilepsy surgery should thus be advised according to the good results (Bautista *et al.*, 2003; Kral *et al.*, 2003; Fauser *et al.*, 2004).

Summary

In many cases of patients with FCD, epilepsy manifests early and is refractory to pharmacological treatment from its beginning. However, in a few patients epilepsy does not become manifest until the second to sixth decade of life. In some patients epilepsy could be controlled over a certain period of time by antiepileptic drugs. Factors contributing to epileptogenicity of FCD and influencing pharmacological treatment of epilepsy are unknown. Possibly, the histological subtype plays a role as seizure onset in patients with cytoarchitectural abnormalities was earlier than in patients with only architectural abnormalities or heterotopic neurons only. Febrile seizures mostly occurred in patients with dual pathology, that is, FCD with an additional hippocampal sclerosis of higher degree. In patients with mild hippocampal damage, febrile seizures are uncommon, and different pathomechanisms may play a role for hippocampal involvement. Seizure semiology seems to be not only dependent on localization but also on the age, and changes

frequently occurred during childhood, but no longer during adult life.

References

- Bast T, Ramantani G, Seitz A, Rating D. Focal cortical dysplasia: prevalence, clinical presentation and epilepsy in children and adults. *Acta Neurol Scand* 2006; 113: 72–81.
- Bastos AC, Comeau RM, Andermann F, Melanson D, Cendes F, Dubeau F, *et al.* Diagnosis of subtle focal dysplastic lesions: curvilinear reformatting from three-dimensional magnetic resonance imaging. *Ann Neurol* 1999; 46: 88–94.
- Bautista JF, Foldvary-Schaefer N, Bingaman WE, Lüders HO. Focal cortical dysplasia and intractable epilepsy in adults: clinical, EEG, imaging, and surgical features. *Epilepsy Res* 2003; 55: 131–6.
- Brekelmans GJF, van Emde Boas W, Velis DN, van Huffelen AC, Debets RMC, van Veelen CWM. Mesial temporal versus neocortical temporal lobe seizures: demonstration of different electroencephalographic spreading patterns by combined use of subdural and intracerebral electrodes. *J Epilepsy* 1995; 8: 309–20.
- Brockhaus A, Elger CE. Complex partial seizures of temporal lobe origin in children of different age groups. *Epilepsia* 1995; 36: 1173–81.
- Cepeda C, Hurst RS, Flores-Hernandez J, Hernandez-Echeagaray E, Klapstein GJ, Boylan MK, *et al.* Morphological and electrophysiological characterization of abnormal cell types in pediatric cortical dysplasia. *J Neurosci Res* 2003; 72: 472–86.
- Chan S, Chin SS, Nordli DR, Goodman RR, DeLaPaz RL, Pedly TA. Prospective magnetic resonance imaging identification of focal cortical dysplasia, including the non-balloon cell subtype. *Ann Neurol* 1998; 44: 749–57.
- Chassoux F, Devaux B, Landre E, Turak B, Nataf F, Varlet P, *et al.* Stereoelectroencephalography in focal cortical dysplasia. A 3D approach to delineating the dysplastic cortex. *Brain* 2000; 123: 1733–51.
- Cusmai R, Dulac O, Diebler C. Lesions focales dans les spasmes infantiles. *Neurophysiol Clin* 1988; 18: 235–41.
- Engel J Jr. Classification of the International League Against Epilepsy: time for reappraisal. *Epilepsia* 1998; 39: 1014–7.
- Fauser S, Schulze-Bonhage A, Honegger J, Carmona H, Huppertz HJ, Pantazis G, *et al.* Focal cortical dysplasias: surgical outcome in 67 patients in relation to histological subtypes and dual pathology. *Brain* 2004; 127: 2406–18.
- Fauser S, Schulze-Bonhage A. Epileptogenicity of cortical dysplasia in temporal lobe dual pathology: an electrophysiological study with invasive recordings. *Brain* 2006; 129: 82–95.
- Fisher PD, Sperber EF, Moshe SL. Hippocampal sclerosis revisited. *Brain Dev* 1998; 20: 563–73.
- Fogarasi A, Janszky J, Faveret E, Pieper T, Tuxhorn I. A detailed analysis of frontal lobe seizure semiology in children younger than 7 years. *Epilepsia* 2001; 42: 80–5.
- Hamati-Haddad A, Abou-Khalil B. Epilepsy diagnosis and localisation in patients with antecedent childhood febrile convulsions. *Neurology* 1998; 50: 917–22.
- Holmes GL, Gairns JL, Chevassus-Au-Louis N, Ben-Ari Y. Consequences of neonatal seizures in the rat: morphological, behavioral effects. *Ann Neurol* 1998; 44: 845–57.
- Huang L, Cilio MR, Silveira DC, McCabe BK, Sogawa Y, Stafstrom CE, *et al.* Long-term effects of neonatal seizures: a behavioral, electrophysiological, and histological study. *Brain Res Dev Brain Res* 1999; 118: 99–107.
- Huppertz HJ, Grimm C, Fauser S, Kassubek J, Mader I, Hochmuth A, *et al.* Enhanced visualization of blurred gray-white matter junctions in focal cortical dysplasia by voxel-based 3-D MRI analysis. *Epilepsy Res* 2005; 67: 35–50.
- Kassubek J, Huppertz HJ, Spreer J, Schulze-Bonhage A. Detection and localization of focal cortical dysplasia by voxel-based 3-D MRI analysis. *Epilepsia* 2002; 43: 596–602.

- Kral T, Clusmann H, Blumcke I, Fimmers R, Ostertun B, Kurthen M, et al. Outcome of epilepsy in focal cortical dysplasia. *J Neurol Neurosurg Psychiatry* 2003; 74: 183–8.
- Kresk P, Tichy M, Belsan T, Zamencnik J, Paulas L, Faladova L, et al. Life-saving epilepsy surgery for status epilepticus caused by cortical dysplasia. *Epileptic Disord* 2002; 4: 203–8.
- Kuzniecky R, Murro A, King D, Morawetz R, Smith J, Powers R, et al. Magnetic resonance imaging in childhood intractable partial epilepsies: pathologic correlations. *Neurology* 1993; 1993: 681–7.
- Kuzniecky R, Morawetz R, Faught E, Black L. Frontal and central lobe focal dysplasia: clinical, EEG, and imaging features. *Dev Med Child Neurol* 1995; 37: 159–66.
- Lortie A, Plouin P, Chiron C, Delalande O, Dulac O. Characteristics of epilepsy in focal cortical dysplasia in infancy. *Epilepsy Res* 2002; 51: 133–45.
- Lüders H, Acharva J, Baumgartner C, Benbadis S, Bleasel A, Burgess R, et al. Semiological seizure classification. *Epilepsia* 1998; 39: 1006–13.
- Lüders H, Acharva J, Baumgartner C, Benbadis S, Bleasel A, Burgess R, et al. A new epileptic seizure classification based exclusively on ictal semiology. *Acta Neurol Scand* 1999; 99: 137–41.
- Misawa S, Kuwabara S, Hirano S, Shibuya K, Arai K, Hattori T. Epilepsia partialis continua as an isolated manifestation of motor cortical dysplasia. *J Neurol Sci* 2004; 225: 157–60.
- Misawa S, Kuwabara S, Shibuya K, Mamada K, Hattori T. Low-frequency transcranial magnetic stimulation for epilepsia partialis continua due to cortical dysplasia. *J Neurol Sci* 2005; 234: 37–9.
- Ng YT, Kim HL, Wheless JW. Successful neurosurgical treatment of childhood complex partial status epilepticus with focal resection. *Epilepsia* 2003; 44: 468–71.
- Palmini A, Andermann F, Olivier A, Tampieri D, Robitaille Y, Andermann E, et al. Focal neuronal migration disorders and intractable partial epilepsy: a study of 30 patients. *Ann Neurol* 1991a; 30: 741–9.
- Palmini A, Andermann F, Olivier A, Tampieri D, Robitaille Y, Melanson D, et al. Neuronal migration disorders: a contribution of modern neuroimaging to the etiologic diagnosis of epilepsy. *Can J Neurol Sci* 1991b; 18: 580–7.
- Palmini A, Lüders HO. Classification issues in malformations caused by abnormalities of cortical development. *Neurosurg Clin N Am* 2002; 37: 1–17.
- Ray A, Kotagal P. Temporal lobe epilepsy in children: overview of clinical semiology. *Epileptic Disord* 2005; 7: 299–307.
- Raymond AA, Fish DR, Stevens JM, Cook MJ, Sisodiya SM, Shorvon SD. Association of hippocampal sclerosis with cortical dysgenesis in patients with epilepsy. *Neurology* 1994; 44: 1841–5.
- Semah F, Picot MC, Adam C, Broglin D, Arzimanoglou A, Bazin B, et al. Is the underlying cause of epilepsy a major prognostic factor for recurrence? *Neurology* 1998; 51: 1256–62.
- Siegel AM, Cascino GD, Elger CE, Devinsky O, Laff R, Najjar S, et al. Adult-onset epilepsy in focal cortical dysplasia of Taylor type. *Neurology* 2005; 64: 1771–4.
- Stephen L, Kwan P, Brodie MJ. Does the cause of localisation-related epilepsy influence the response to antiepileptic drug treatment? *Epilepsia* 2001; 42: 357–62.
- Tassi L, Colombo N, Garbelli R, Francione S, Lo Russo G, Mai R, et al. Focal cortical dysplasia: neuropathological subtypes, EEG, neuroimaging and surgical outcome. *Brain* 2002; 125: 1719–32.
- Widdess-Walsh P, Kellinghaus C, Jeha L, Kotagal P, Prayson R, Bingaman W, et al. Electro-clinical and imaging characteristics of focal cortical dysplasia: correlation with pathological subtypes. *Epilepsy Res* 2005; 67: 25–33.
- Wilke M, Kassubek J, Ziyeh S, Schulze-Bonhage A, Huppertz HJ. Automated detection of gray matter malformations using optimized voxel-based morphometry: a systematic approach. *Neuroimage* 2003; 20: 330–43.
- Wyler AR, Hermann BP, Somes G. Extent of medial temporal resection on outcome from anterior temporal lobectomy: a randomized prospective study. *Neurosurgery* 1995; 37: 982–91.
- Yoshimura K. A case of nonconvulsive status epilepticus associated with focal cortical dysplasia. *Brain Dev* 2003; 25: 207–10.